

Models of Focal Cerebral Ischemia in the Nonhuman Primate

Shunichi Fukuda and Gregory J. del Zoppo

Abstract

Ischemic stroke is a uniquely human disease syndrome. Models of focal cerebral ischemia developed in nonhuman primates provide clinically relevant platforms for investigating pathophysiological alterations associated with ischemic brain injury, microvascular responses, treatment responses, and clinically relevant outcomes that may be appropriate for ischemic stroke patients. A considerable number of advantages attend the use of nonhuman primate models in cerebral vascular research. Appropriate development of such models requires neurosurgical expertise to produce single or multiple vascular occlusions. A number of experimentally and clinically accessible outcomes can be measured, including neurological deficits, neuron injury, evidence of non-neuronal cell injury, infarction volume, real-time imaging of injury development, vascular responses, regional cerebral blood flow, microvascular events, the relation between neuron and vascular events, and behavioral outcomes. Nonhuman primate models of focal cerebral ischemia provide excellent opportunities for understanding the vascular and cellular pathophysiology of cerebral ischemic injury, which resembles human ischemic stroke, and the appropriate study of pharmacological interventions in a human relevant setting.

Key Words: arterial occlusion; cerebral ischemia; microvessel; neuron; nonhuman primate; stroke; transorbital outcomes

Introduction

Ischemic stroke is a uniquely human disease syndrome. Although elements of atheroma formation and vascular injury have been induced in small animals, the development of cerebrovascular disease and thromboembolic events from the platform of arterial disease as in humans has so far not been consistently possible in other species.

Animal models of ischemic or hemorrhagic stroke have offered mimics of the disease (e.g., single arterial occlusion with downstream ischemia) or disease elements (e.g., em-

bolism). Concerns have arisen about limitations in modeling the processes of focal cerebral ischemia that are still relevant (del Zoppo 1990a,b; Ginsberg and Busto 1989; Zivin and Grotta 1990). Rodent models offer much in versatility, cost savings, and utility for statistical analysis, but they have not generally translated testable interventions into clinical benefit (Ginsberg and Busto 1989; Zivin and Grotta 1990). In addition, although much benefit has been gained from the use of rodent models in understanding the effects of ischemia on neuron function and survival (Astrup et al. 1981; Siesjö 1992), concerns about altered development in murine genetic constructs, species differences at all levels, and outcome measures (molecular, cellular, and behavioral), which do not reflect human cognates, are potential limitations to their use.

Modeling of ischemic stroke in the nonhuman primate has addressed some of these concerns, including specific technical issues involved with the vascular anatomy of the brain and biological differences resulting from the phylogenetic distance of smaller animals from humans. Indeed, genomic differences may in the future prove insurmountable in allowing translation of experimental work to clinical intervention (Enard et al. 2002). Nonhuman primates used in stroke-related models provide opportunities for hypothesis testing and for translation to ischemic stroke intervention.

In particular, the nonhuman primate has been central to the development of concepts or procedures currently valued in stroke research. These areas include measurements of regional cerebral blood flow (rCBF¹), the “ischemic penumbra,” microvessel reactivity, cellular inflammation, contributors to focal “no-reflow” and infarction, and behavioral aspects of recovery (Abumiya et al. 1999; Astrup et al. 1981; Branston et al. 1974, 1976, 1977, 1984; del Zoppo et al. 1986a, 1988a, 1990, 1991, 1992b; Garcia and Kamijyo 1974; Garcia et al. 1971, 1983a,b; 1995b; Heo et al. 1999; Hosomi et al. 2001; Schmid-Schönbein and del Zoppo 1993).

It has been suggested that interventional studies should be performed in primates before testing in human patients (STAIR 1999). However, this practice is unusual. Although

Shunichi Fukuda, M.D., Ph.D., Research Associate, and Gregory J. del Zoppo, M.D., Associate Professor, are in the Department of Molecular and Experimental Medicine, The Scripps Research Institute, La Jolla, California.

¹Abbreviations used in this article: ACA, anterior cerebral artery; A1, proximal segment of ACA; CT, computerized tomography; ICA, internal carotid artery; LSA, lenticulostriate artery; MCA, middle cerebral artery; MCAO, middle cerebral artery occlusion; M1, proximal segment of MCA; MRI, magnetic resonance imaging; PMN, polymorphonuclear; rCBF, regional cerebral blood flow.

pharmacokinetic, pharmacodynamic, and toxicology studies routinely use primates, formal studies with stroke models are not generally performed beyond those involving rodents. Most often, rather than a prelude for testing in humans, the primate is used for discovery research and target setting.

Characteristics of Primate Species in Model Systems

Models of focal cerebral ischemia in the primate have used single arterial occlusion (e.g., middle cerebral artery [MCA¹] occlusion) or occlusion of multiple supply arteries to achieve a region of ischemic injury (Branston et al. 1974; del Zoppo et al. 1986a; Garcia and Kamijyo 1974; Garcia et al. 1971; Spetzler et al. 1980). The relative reproducibility of stroke-related findings and the similar variability in injury volume make the nonhuman primate a clinically relevant platform for the study of acute focal carotid territory (proximal MCA) ischemia/infarction with direct applicability to human focal cerebrovascular ischemia.

The most humane and serviceable awake model is that of the *Papio* species, with the transorbital surgical approach to the MCA (Branston et al. 1974; del Zoppo et al. 1986a; Garcia and Kamijyo 1974; Spetzler et al. 1980). Properly performed, this approach allows rapid recovery of the subject with full function (del Zoppo et al. 1986a). The current method is a refinement of the approach devised by Symon and colleagues nearly 30 yr ago (Branston et al. 1974, 1976, 1977; Garcia and Kamijyo 1974). Others have used the model and approach to examine responses of the striatum and cortex to proximal segment (M1¹) MCA occlusion (MCAO¹) (del Zoppo et al. 1986a). Approximately 40 to 60% of subjects display both cortical and subcortical injury, and the remainder experience only striatal injury (Spetzler et al. 1980). Alternative model systems to the reversible MCAO preparation in the awake animal involve reversible ligation of the MCA (Crowell et al. 1981; del Zoppo et al. 1986a; Spetzler and Selman 1979).

One major advantage of the transorbital approach to the proximal MCA is that it is more humane than a craniotomy for survival procedures because it leaves the subject without a cranial defect and the related potential disabilities. Furthermore, it does not disturb brain tissue, alter vascular structures, or require intensive care after recovery to restrain the subject. Recovery from the surgical procedure is typically rapid. This approach has been applied to cats in addition to larger primates, in which the arterial anatomy is appropriate (i.e., like humans) (Sundt and Waltz 1966). Although early work using this approach in the nonhuman primate resulted in substantial mortality due to permanent occlusion of the proximal MCA (Hudgins and Garcia 1970), the survivability is 100% in the present model by reperfusion of the blood flow through the MCA (del Zoppo et al. 1986a; Spetzler and Selman 1979).

The nonhuman primate has been used for vascular studies because the hemostatic components, including platelets, plasma coagulation and fibrinolytic and inhibitor proteins, and polymorphonuclear (PMN¹) leukocytes are more similar to humans in ultrastructure, antigenicity, function (kinetics), and concentration than in rodents (Hanson and Harker 1987). Advantages of this species and models also include the following:

1. The cerebral vascular anatomy is analogous to the human but differs from other lower species (e.g., the basal ganglia is unlike that of the rat) (Edvinsson et al. 1993).
2. Primates are gyrencephalic and have substantial subcortical white matter, unlike rodents.
3. Primate MCA stroke models provide a reproducible and defined predictable nonfatal cerebral infarction in a single vascular territory of the MCA branches (lenticulostriatal arteries [LSAs¹]).
4. MCA flow obstruction is nonthrombotic with arterial compression models.
5. MCA flow obstruction is elective, allowing convenient study of clinically relevant outcomes distant from the surgical implantation procedure, thereby avoiding the confounding variables of surgery and anesthesia on cellular function (Ember et al. 1994).
6. Elective MCA reperfusion allows access of blood components to the ipsilateral LSA and the study of the effects of reperfusion injury (del Zoppo et al. 1990).
7. The awake model is “closed,” thereby maintaining the intracranial pressure of the intact cranium and the normal (37–38°C) temperature of the central nervous system, conditions not always met in “open” models.
8. The pathological changes following sustained MCA occlusion are typical of complete cerebral infarction (Garcia and Conger 1987; Tagaya et al. 1997).
9. A highly relevant new aspect of focal cerebral ischemia modeling is the significantly greater rapidity of neuron injury in the primate basal ganglia compared with the rat caudate-putamen (Tagaya et al. 1997) and relevant differences in microvascular anatomy in those regions (Edvinsson et al. 1993; Paxinos and Watson 1986).
10. Models of this (and similar) species have been the subject of rCBF/neuropathology correlations (Jones et al. 1981; Yonas et al. 1990), and selected local cerebral blood flow studies with the nontoxic, noninvasive nuclear magnetic resonance imaging (MRI¹) of ¹⁴F-trifluoromethane (unpublished data; Branch et al. 1991), which confirm the relation between low rCBF and infarction.
11. Its size makes *Papio* species suitable for serial clinical (e.g., objective neurological assessment, computerized tomography [CT¹] cerebral scan, MRI scan, carotid angiography, neuroelectrophysiological measurements, and neuropathology) and laboratory investigations. This attribute is important in designing clinically relevant experiments.

A singular advantage of the nonhuman primate is the opportunity to apply agents under development for use in humans directly, before their extension to the clinical arena. This is a particular advance for substances that can alter hemostatic/vascular dynamics. Distinct (often paradoxical) differences between the hemostatic and vascular mechanisms in rodents/rabbits and their responses to antithrombotic and fibrinolytic agents in comparison with those of humans are well known and limit the use of specific interventions in those species. For instance, rodent platelets lack platelet activating factor (PAF¹) receptors and behave paradoxically to aspirin (ASA) (Shinozaki et al. 1992). Whereas polymorphonuclear (PMN¹) leukocyte platelet aggregates occur in the ischemic zone during MCAO in the primate and have been demonstrated in humans (Grau et al. 1994), they have not been shown to occur in rats (Garcia et al. 1994). For PMN leukocyte adhesion, integrin $\alpha_4\beta_1$ is exposed on rat leukocytes but not on the human cells (Davenpeck et al. 1998). Immunoprobes raised in rodents against human proteins/epitopes for research/therapeutic purposes generally cross-react with baboon epitopes but not other lower mammals, a distinction of particular relevance.

Disadvantages of the nonhuman primate model are relative and include the following:

1. Development and maintenance of the model requires a facility specifically staffed and equipped to care for nonhuman primates.
2. Appropriate high-quality surgical and imaging facilities for preparation of the model(s) and for quantitation of outcomes are required.
3. The dedication of professional individuals with appropriate surgical, scientific, and organizational skills to perform high quality investigations is necessary. Appropriate certification and support by federal and scientific organizations to verify these attributes validate the procedural and experimental aspects of this model.
4. The significant expense, relative to smaller nonprimate species, is the principal disadvantage of this species. A recent limitation of the availability of primates stems from market restrictions on transport of feral animals into this country. However, this aspect should not be a deterrent in the face of the unique advantages of high-quality scientific and medical investigations. Indeed, the current experiment configurations provide significant quantities of high-quality tissue preparations that are suitable for multiple studies. In this way, the impact of expense is greatly reduced.

Despite the differences in expense and the cohort sizes achievable between small animal models and nonhuman primate models, current clinical experience has shown the need for investigations of vascular therapies to proceed through appropriate primate models before their use in patients. This reason, the current availability of agents and molecular probes that are relevant to human vascular structure, and the development of a well-characterized and rel-

evant primate model of focal ischemia/reperfusion support the research use of the primate.

Formulation of the Primate Models

Species

For the nonhuman primate stroke model, squirrel monkeys, macaques, and baboons have been used in various design formats. Among these primates, the *Papio* species is the largest and has proven the most accessible for exploratory and interventional studies. Currently, there is little difference among the three types in terms of cost.

Cerebrovascular Anatomy

Primates have a complete Circle of Willis. Moreover, distribution of the MCA and its branches in primates is identical or similar to that in humans. Baboons may have a singular anterior cerebral artery (ACA¹), and LSA branches can arise from the internal carotid artery (ICA¹), although this situation is unusual. It should be noted that variability in local vascular anatomy can occur. In baboons, like humans, there is rich collateral circulation in the brain, and M1 occlusion in baboons results mainly in basal ganglia and white matter ischemia. Cortical ischemia is variable. This situation mimics human M1 MCA ischemia and is quite distinct from the injury caused by MCA occlusion in rodents, which lack similar collateral protection.

Location of Arterial Occlusion

Most of the surgically prepared primate stroke models involve occlusion of the M1 segment of the MCA, which mimics ischemic injury in approximately 10% of human stroke. Several investigators, however, have developed stroke models using occlusion in the ACA territory or that producing thalamic infarction (Hudgins and Garcia 1970; Vajda et al. 1985).

Surgical Approaches

There are four major surgical approaches to the branches of the Circle of Willis, which primarily involve the occlusion of the MCA or ICA to produce focal symptoms: (1) the intracranial approach along the sphenoidal wing, (2) the retro-orbital approach, (3) the transorbital approach, and (4) complex interventional approaches (see Characteristics of Primate Species in Model Systems, Transorbital Surgical Approach below, and Table 1). The intracranial approach is similar to the trans-Sylvian approach used in clinical neurosurgery (Symon 1975; Young et al. 1997). In the retro-orbital approach, the sphenoidal wing is removed and the

Table 1 Nonhuman primate stroke models

| Sources ^a | Species ^b | Location ^b | Approach ^b | T/P ^b | Aw/An ^b | Purpose ^b |
|--------------------------|----------------------|-------------------------|-----------------------|------------------|--------------------|---|
| Clippings | | | | | | |
| Hudgins and Garcia 1970 | Squirrel | Proximal M1 | TO | P | An | Neuropathology |
| Clipping | | | | | | |
| Symon 1975 | Baboon | Proximal/distal M1 | TO | P | An | CBF |
| Liu et al. 1992 | Baboon | Bilateral A1 | TO | P | An | CBF |
| Young et al. 1997 | Baboon | Proximal/distal M1 | TO | T/P | An | Effect of reperfusion on infarct volume |
| Frazer et al. 1998 | Baboon | Proximal M1 | TO | T | An | Effect of RTN of t-PA on infarct volume |
| Huang et al. 2000 | Baboon | Bilateral A1/distal ICA | TO | T | An | Larger infarction volume |
| Balloon occluder | | | | | | |
| Spetzler and Selman 1979 | Baboon | Proximal M1 | TO | T | Aw | Repeatable stroke model in awake condition |
| del Zoppo et al. 1986a,b | Baboon | Proximal M1 | TO | T | Aw | Multiple studies, microvascular degradation due to ischemia |
| Coagulation | | | | | | |
| Yonas et al. 1990 | Baboon | Lenticulostriate a. | RO | P | An | Basal ganglia infarction |
| Clipping | | | | | | |
| Crowell et al. 1970 | Macaque | Proximal M1 | IC | T | An | Neuropathology |
| Snare ligation | | | | | | |
| Crowell et al. 1981 | Macaque | Proximal M1 | IC | T/P | Aw | Time course of ischemic injury |
| Embolization | | | | | | |
| Molinari et al. 1974 | Macaque | M1 | IV | P | Aw | Stroke model without craniotomy |
| Watanabe et al. 1977 | Macaque | ICA bifurcation | IV | P | An | Stroke model without craniotomy |

^aSee text.

^bAn, anesthetized; Aw, awake; CBF, cerebral blood flow; IC, intracranial; ICA, internal carotid artery; IV, intravenous; M1, primary motor cortex; P, permanent; RO, retro-orbital; RTN, retrograde transvenous neuroperfusion; T, temporal; TO, transorbital; t-PA, tissue plasminogen activator.

orbit and intracranial cavity are opened without opening the dura. The transorbital approach is considered separately (see Transorbital Surgical Approach). In the interventional approach, emboli (e.g., silicone cylinders) are injected from the extracranial carotid artery bifurcation to occlude the intracranial ICA bifurcation (Molinari et al. 1974; Watanabe et al. 1977). Because this technique requires neck surgery without craniotomy, it can be performed with local anesthesia and it leads to vessel occlusion in an awake state.

Techniques

There are several techniques to occlude cerebral arteries: clipping, occlusion by an extrinsic balloon device or snare ligature, electrocoagulation or photocoagulation, and embolization with an interventional approach. Electrocoagulation and embolization cause permanent occlusion of the vessel, although it is often unclear whether intravascular occlusion

by the coagulation method is complete. This matter can be evaluated by direct observation if a transorbital window is used. In contrast, the use of clip or extrinsic balloon occlusion enables reperfusion of blood flow by temporary vessel occlusion.

The most important difference between clipping and balloon occlusion is whether the vessel is occluded in an anesthetized or awake condition. The major advantage of the awake condition is that the examiner can observe how the vessel occlusion affects the neurological condition of the animal. Within 5 min after vessel occlusion, the animal usually presents contralateral hemiparesis, hemianopsia, and hemifacial paresis. The awake condition enables temporary occlusion without any side effects due to anesthesia, and it is similar to the clinical situation in human ischemic stroke. For example, ischemic stroke usually induces an increase in mean arterial blood pressure (MAP¹) in compensation for vessel occlusion, whereas the MAP of the anesthetized animal is maintained constant before and after vessel occlusion. In the awake condition, MAP is not gen-

erally monitored, but it has been shown not to deviate from normal (data not shown).

Infarction volume following M1 MCA occlusion is smaller in the anesthetized preparation than during awake experiments (del Zoppo et al. 1986a; Molinari et al. 1974). This difference may occur partly because inhaled anesthetics, such as halothane, cause transient depression of leukocyte chemotaxis (Ember, et al 1994; Moudgil et al. 1981, 1984). This depression may contribute to reduction of neutrophil migration into the brain tissue, leading to smaller infarction volumes. Well-controlled MAP and supply of O₂, and neuronal “inactivation” by anesthetics such as barbiturates, may also contribute to smaller infarct volumes. In contrast, clipping is technically easier than placement of an extrinsic balloon occlusion device. In the anesthetized condition, physiological conditions can be standardized among animals, which may be convenient for evaluation of the effect of a test agent on infarction volume. The results would not be expected to be the same as the awake condition if the agent affects physiological conditions.

Transorbital Surgical Approach

The transorbital surgical approach is a technically demanding procedure and requires the skills of the clinical neurosurgeon. The surgical procedure is performed under inhalational anesthesia and involves the use of isoflurane anesthesia (5% induction, 1.5-2.5% maintenance), with O₂ supplementation (1.5 L/min). Anatomically, the ICA bifurcation lies directly posterior to the orbit. To gain access to these vascular structures, enucleation is followed by transection of the optic nerve and ophthalmic artery. Bleeding is stopped with electrocoagulation. Angiography has demonstrated that the MCA and ICA remain patent after these procedures. A small craniotomy (~1 cm diameter) is made by removal of the medial sphenoid wing and portions of the adjacent middle fossa with a high-speed pneumatic drill. Under microscopic view (300-mm objective lens), the optic strut is also removed to open the optic foramen. The dura is then opened, and the Sylvian fissure is opened with an arachnoid knife and microscissors to identify the top of the ICA, the ACA, and the MCA.

Microsurgical technique enables exposure of the MCA from the surrounding arachnoid membranes (Figure 1). When dissection of the MCA and the LSA bundles is complete, the extrinsic balloon occlusion device is placed around the MCA proximal to the take-off of the LSA and fixed with 4-0 silk (Spetzler and Selman 1979). After covering the craniotomy with Gelfoam (Pharmacia-Upjohn, Kalamazoo, MI), the enucleated orbit is filled with radiolucent methylmethacrylate (impregnated with antibiotics). The proximal terminus of the connector tube is placed subcutaneously under the scalp in a tunnel prepared for this purpose, and the orbital site is surgically closed.

Postoperative recovery typically occurs within 1 to 2 hr without any neurological deficit. The animals are fully ac-

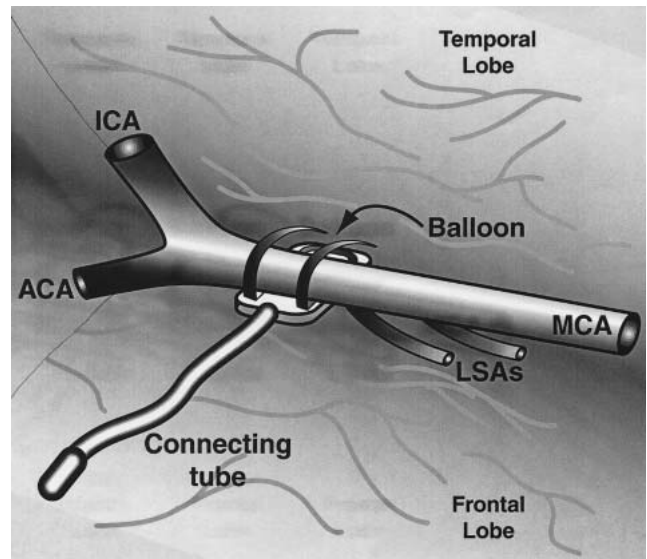


Figure 1 Placement of the balloon occluder on the middle cerebral artery (MCA). The balloon occluder is placed around the middle artery proximal to lenticulostriate arteries with 4-0 silk. The proximal terminus of connecting tube is placed subcutaneously under the scalp. ACA, anterior cerebral artery; ICA, internal carotid artery; LSAs, lenticulostriate arteries.

tive within 4 to 6 hr. Neurological function is monitored for an additional 2 days before any experimental procedure. The surgical preparation of this primate model offers several logistical advantages over other models (Symon 1975): The transorbital approach is superior to techniques requiring a lateral craniotomy for exposure of the MCA in that the latter leaves a significant residual dural defect, is a more prolonged procedure with increased attendant morbidity and mortality, and does not allow sufficiently proximal placement of the occlusion device. Furthermore, the device is self-contained, unexposed, and requires no maintenance after placement. In addition, the animals are not constrained by the presence of the device after initial convalescence. Finally, vascular structures are not disrupted or perturbed by this approach, in contrast to the lateral craniotomy approach.

Limitations associated with this surgical approach include the requirement of an experienced neurosurgical team to carry out the transorbital approach and placement of the device, and the exposure of the animal to a somewhat prolonged (1- to 2-hr) anesthetic risk. This model, however, allows controlled evaluation of the effects of potentially ischemia-sparing agents in acute stroke with clinically relevant techniques.

Outcomes

To evaluate pharmacological interventions and understand biological responses, it is essential to study a number of

clinically and experimentally accessible outcomes. The text below briefly describes neurological outcome, neuron injury, evidence of cell injury, infarction volume, imaging in real-time, vascular consequences, rCBF, microvascular events, neuron and vascular events, behavioral outcomes, in relation to human ischemic stroke.

Neurological Outcome

The nonhuman primate enables clinical evaluation of neurological deficits generated by single arterial occlusion (Spetzler and Selman 1979; Spetzler et al. 1980). In the awake nonhuman primate, neurological deficits of variable severity (including contralateral central hemifacial hemiparesis) and visual field cuts can be detected within minutes of proximal MCAO; striatal injury can be documented as early as 1 hr after onset of ischemia (del Zoppo et al. 1986a). Neurological assessment scales are simple, motor weighted, and generally reproducible (del Zoppo et al. 1986a; Spetzler and Selman 1979; Spetzler et al. 1980). The scales reflect deficits exhibited by ischemic injury to identical arterial territories in human patients. Reports of pharmacological interventional studies using such scales are few (Abumiya et al. 2000; Mori et al. 1992, 1995; Thomas et al. 1993) but provide an indication of the variability in outcomes that mimic those of human ischemic stroke (Mori et al. 1995). Although not validated, much like stroke scales used to assess stroke type and severity, these scoring instruments are descriptive and merely semiquantitative.

Neuron Injury

In unanesthetized nonhuman primate preparations, neurological deficits develop rapidly, in a manner identical to human stroke (del Zoppo et al. 1986a; Spetzler et al. 1980). Transient MCA occlusion can produce residual injury, which is time dependent and permanent (Tagaya et al. 1997, 2001). Tagaya and colleagues demonstrated that more than 80% of neurons in the ischemic striatum developed evidence of DNA scission within 2 hr of MCAO, significantly more rapidly than in a typical anesthetized rodent stroke model preparation (Tagaya et al. 1997). Garcia and colleagues showed rapid alterations in neuron ultrastructure following MCAO in the primate (Garcia and Kamijyo 1974; Garcia et al. 1971, 1977, 1983a,b).

Evidence of Cell Injury

Selective neuronal vulnerability occurs in global cerebral ischemia (Ginsberg and Busto 1989; Pulsinelli 1985; Pulsinelli and Duffy 1983; Pulsinelli et al. 1982) and is also evident following MCAO in the nonhuman primate (Tagaya et al. 1997) and the rodent (Garcia et al. 1993, 1995a). Ultrastructural alterations occur simultaneously in astro-

cytes, oligodendrocytes, and microvascular cells (Garcia and Kamijyo 1974; Garcia et al. 1977, 1983b). Secondary injury is generated by cellular inflammation, which involves adhesion and transmigration of PMN leukocytes and other leukocytes (del Zoppo et al. 1991; Garcia et al. 1995a; von Andrian et al. 1991). These developments require immediate responses of the microvasculature to MCAO (see below). The cellular changes noted here contribute to the developing territorial infarction.

Infarction Volume

Infarction is evident by conventional neuropathology within 24 hr of arterial occlusion in the nonhuman primate (del Zoppo et al. 1986a). MCAO generates infarction with cystic cavity formation involving the striatum, subcortical white matter, and cortex to a variable extent. To generate a larger infarction volume, Huang and colleagues used a multiple clipping technique of the ICA and both A1 ACAs to attenuate the collateral circulation from the ACA to the MCA territory. Although the method provided larger areas of infarction, which routinely included the cortex, they observed greater interanimal variability in infarction volume (Huang et al. 2000). The occlusion period was limited to 1 hr, because extended ischemia by multiple clipping is quite severe. Similarly, MCAO beyond 3 hr in the awake preparation is associated with increased hemispheric swelling and significant early mortality (del Zoppo et al. 1986a).

Imaging in Real-Time

Radiographic techniques have been used to assess injury development in focal cerebral ischemia (von Kummer and Weber 1997; von Kummer et al. 1995). CT scan and MRI offer increasingly sensitive modalities for injury volume determinations. In one experimental study, detection of hemorrhage was assessed by CT scan following use of recombinant tissue plasminogen activator in a clinically relevant setting (del Zoppo et al. 1988a, 1990, 1992a; Mori et al. 1988). Conventional angiography has been used to confirm recanalization of the MCA in selected studies (del Zoppo et al. 1986b; Michenfelder and Milde 1975). Although imaging is feasible, each approach requires administration of anesthesia, which can interfere with injury development (Kawaguchi et al. 2000).

Vascular Consequences

Vasospasm can induce ischemia in distal areas. A concern is whether surgery for balloon device placement or clipping of the MCA might impair the vessel and perivascular components either permanently or temporarily. Microscopic surgical technique can cause temporary vasospasm of the MCA. However, careful operative technique prevents se-

vere spasm. Treatment with papaverine serves to reduce vasospasm. According to Dodson and coworkers, surgical clipping can cause damage to vascular smooth muscle cells and the perivascular nerve supply (Dodson et al. 1974). However, because appropriate neurosurgical treatment with temporary clipping of major cerebral arteries usually does not cause any neurological deficit or brain injury detectable by MRI or CT scan, careful surgery can avoid such effects on the brain in the animals.

Regional Cerebral Blood Flow (rCBF)

Symon and colleagues demonstrated that rCBF is significantly reduced in the striatum of the nonhuman primate immediately following MCAO (Branston et al. 1974, 1976, 1984). Those observations contributed two important elements to the understanding of focal ischemia: (1) rCBF does not cease following MCAO, and (2) rCBF increases with distance from the core of injury (Branston et al. 1974). The latter finding has been taken as support for the existence of an “ischemic penumbra” of potentially recoverable tissue surrounding the ischemic core (Astrup et al. 1981). rCBF measurements have been made with a number of techniques (Okada et al. 1994; Rosenblum and Wormley 1995). Real-time rCBF measurements are not possible in awake preparations.

Microvascular Events

Nonhuman primate preparations have been central to the evaluation of important changes in microvessel biology heretofore not appreciated. MCAO initiates activation of microvessel components and sequential expression of cellular adhesion receptors on microvascular endothelium (Connolly et al. 1996). Structural and matrix-related alterations occur also in microvessels within the ischemic core immediately following MCAO in the awake preparation (Hamann et al. 1995). Leukocyte adhesion has been associated with focal “no-reflow” (Mori et al. 1992). In addition, thrombotic occlusion of the ischemic microvasculature occurs (del Zoppo et al. 1998).

Neuron and Vascular Events

Investigations of neuron injury mechanisms and microvessel responses to focal cerebral ischemia have proceeded separately until recently. The nonhuman primate provides sufficient tissue (due to the larger size of cognate human structures in the brain) to examine the interaction of microvessels with their dependent neurons (the “neurovascular unit”).

Behavioral Outcomes

Although amenable to the evaluation of cognitive and behavioral alterations initiated by focal cerebral ischemia,

little formal study of these attributes has proceeded in the primate. Cooperation by the subject is required for iterative assessments, which is much easier to obtain in the human patient. Impairment of cognition by the ischemic injury may confound even simple assessments of motor dysfunction. Therefore, such outcome evaluations are motor weighted and quite simplistic (del Zoppo et al. 1986a; Spetzler et al. 1980). An elegant contrast is the work of Nudo and colleagues, who have examined the effects of cortical reorganization following directed injury to defined cortical subregions on behavior (Kleim et al. 1998; Nudo and Miliken 1996).

Relation to Human Ischemic Stroke

In humans, there are three major kinds of ischemic stroke: cerebral atherothromboembolism, in situ thrombosis, and lacunar stroke. Among them, cerebral embolism occurs if thrombi originating from the heart or carotid artery atheromata occlude cerebral arteries (usually the ICA or MCA [especially the M1 portion]) and cause infarction in the MCA territories. Therefore, several nonhuman primate stroke models make possible the study of cerebral ischemia in conditions very similar to human cerebral embolism without the impact of thrombus on the ischemic territory.

Conclusions

Nonhuman primate stroke models have a number of advantages because their vascular and brain structures are identical to or closely resemble cognate human structures in their anatomy, morphology, cellular physiology, and biochemistry. The species and models are uniquely useful in research on the cerebrovascular pathophysiology of focal ischemia, which resembles human ischemia. Furthermore, the effects on cerebral ischemia of specific treatments with pharmacological agents and early reperfusion, as well as other untested strategies including hypothermia, suggest application to patients in comparable settings.

References

- Abumiya T, Fritridge R, Mazur C, Copeland BR, Koziol JA, Tschopp JF, Pierschbacher MD, del Zoppo GJ. 2000. Integrin ($\alpha_{IIb}\beta_3$) inhibitor preserves microvascular patency in experimental acute focal cerebral ischemia. *Stroke* 31:1402-1410.
- Abumiya T, Lucero J, Heo JH, Tagaya M, Koziol JA, Copeland BR, del Zoppo GJ. 1999. Activated microvessels express vascular endothelial growth factor and integrin $\alpha_v\beta_3$ during focal cerebral ischemia. *J Cereb Blood Flow Metab* 19:1038-1050.
- Astrup J, Siesjö BK, Symon L. 1981. Thresholds in cerebral ischemia—The ischemic penumbra. *Stroke* 12:723-725.
- Branch CA, Ewing JR, Butt SM, Helpert JA, Welch KMA. 1991. Signal to noise and acute toxicity of a quantitative NMR imaging measure-

- ment of cerebral perfusion in baboons. *J Cereb Blood Flow Metab* 11(Suppl 2):S778-S778.
- Branston NM, Ladds A, Symon L, Wang AD, Vajda J. 1984. Somatosensory evoked potentials in experimental brain ischemia. *Prog Brain Res* 62:185-199.
- Branston NM, Symon L, Crockard HA. 1974. Relationship between the cortical evoked potential and local cortical blood flow following acute middle cerebral artery occlusion in the baboon. *Exp Neurol* 45:195-208.
- Branston NM, Symon L, Crockard HA. 1976. Recovery of the cortical evoked response following middle cerebral artery occlusion in baboons: Relation to local blood flow and PO₂. *Stroke* 7:151-157.
- Branston NM, Symon L, Strong AJ. 1977. Measurements of autoregulation impairment and low-reflow related to cortical rCBF in acute experimental ischaemia in baboons. *Acta Neurol Scand* 64:370-371.
- Connolly ES Jr, Winfree CJ, Springer TA, Naka Y, Liao H, Yan SD, Stern DM, Solomon RA, Gutierrez-Ramos JC, Pinsky DJ. 1996. Cerebral protection in homozygous null ICAM-1 mice after middle cerebral artery occlusion. Role of neutrophil adhesion in the pathogenesis of stroke. *J Clin Invest* 97:209-216.
- Crowell RM, Olsson Y, Klatzo I, Ommaya A. 1970. Temporary occlusion of the middle cerebral artery in the monkey: Clinical and pathological observations. *Stroke* 1:439-448.
- Crowell RM, Marcoux FW, De Girolami U. 1981. Variability and reversibility of focal cerebral ischemia in unanesthetized monkeys. *Neurology* 31:1295-1302.
- Davenpeck KL, Sterbinsky SA, Bochner BS. 1998. Rat neutrophils express $\alpha 4$ and $\beta 1$ integrins and bind to vascular cell adhesion molecule-1 (VCAM-1) and mucosal addressin cell adhesion molecule-1 (MAdCAM-1). *Blood* 91:2341-2346.
- del Zoppo GJ. 1990a. Fibrinolytic agents in animal models of cerebrovascular ischemia. *Fibrinolysis* 4(Suppl 2):3-7.
- del Zoppo GJ. 1990b. Relevance of focal cerebral ischemia models. Experience with fibrinolytic agents. *Stroke* 21:IV-155-IV-160
- del Zoppo GJ, Copeland BR, Anderchek K, Hacke W, Koziol JA. 1990. Hemorrhagic transformation following tissue plasminogen activator in experimental cerebral infarction. *Stroke* 21:596-601.
- del Zoppo GJ, Copeland BR, Hacke W, Dietrich JE, Harker LA. 1988a. Intracerebral hemorrhage following rt-PA infusion in a primate stroke model. *Stroke* 19:134-134.
- del Zoppo GJ, Copeland BR, Harker LA, Waltz TA, Zyroff J, Hanson SR, Battenberg E. 1986a. Experimental acute thrombotic stroke in baboons. *Stroke* 17:1254-1265.
- del Zoppo GJ, Copeland BR, Waltz TA, Zyroff J, Plow EF, Harker LA. 1986b. The beneficial effect of intracarotid urokinase on acute stroke in a baboon model. *Stroke* 17:638-643.
- del Zoppo GJ, Ferbert A, Otis S, Brückmann H, Hacke W, Zyroff J, Harker LA, Zeumer H. 1988b. Local intra-arterial fibrinolytic therapy in acute carotid territory stroke: A pilot study. *Stroke* 19:307-313.
- del Zoppo GJ, Higashida RT, Furlan AJ, Pessin MS, Rowley HA, Gent M, and the PROACT Investigators. 1998. PROACT: A phase II randomized trial of recombinant pro-urokinase by direct arterial delivery in acute middle cerebral artery stroke. *Stroke* 29:4-11.
- del Zoppo GJ, Poock K, Pessin MS, Wolpert SM, Furlan AJ, Ferbert A, Alberts MJ, Zivin JA, Wechsler L, Busse O, Greenlee R, Jr., Brass L, Mohr JP, Feldmann E, Hacke W, Kase CS, Biller J, Gress D, Otis SM. 1992a. Recombinant tissue plasminogen activator in acute thrombotic and embolic stroke. *Ann Neurol* 32:78-86.
- del Zoppo GJ, Schmid-Schönbein GW, Mori E, Copeland BR, Chang C-M. 1991. Polymorphonuclear leukocytes occlude capillaries following middle cerebral artery occlusion and reperfusion in baboons. *Stroke* 22:1276-1284.
- del Zoppo GJ, Yu J-Q, Copeland BR, Thomas WS, Schneiderman J, Morrissey J. 1992b. Tissue factor location in non-human primate cerebral tissue. *Thromb Haemost* 68:642-647.
- Dodson RF, Tagashira Y, Chu LW. 1974. Acute ultrastructural changes in the middle cerebral artery due to the injury and ischemia of surgical clamping. *J Neurol Sci* 3:23-27.
- Edvinsson L, MacKenzie ET, McCulloch J. 1993. General and comparative anatomy of the cerebral circulation. In: Edvinsson L, MacKenzie ET, McCulloch J, eds. *Cerebral Blood Flow and Metabolism*. New York: Raven Press. p 3-39.
- Ember JA, del Zoppo GJ, Mori E, Thomas WS, Copeland BR, Hugli TE. 1994. Polymorphonuclear leukocyte behavior in a non-human primate focal ischemia model. *J Cereb Blood Flow Metab* 14:1046-1054.
- Enard W, Khaitovich P, Kose J, Zollner S, Heissing F, Giavalisco P, Nieselt-Struwe K, Muchmore E, Varki A, Ravid R, Doxiadis GM, Bontrop RE, Paabo S. 2002. Intra- and interspecific variation in primate gene expression patterns. *Science* 296:340-343.
- Frazee JG, X Luo G, Hinton DS, Hovda, DA, Shiroishi MS, Barcliff LT. 1998. Retrograde transvenous neuroperfusion: A back door treatment for stroke. *Stroke* 29:1912-1916.
- Garcia JH, Conger KA. 1987. Light and electron-microscopic features of brain ischemia. In: Wood JH, ed. *Cerebral Blood Flow. Physiologic and Clinical Aspects*. New York: McGraw Hill. p 75-91.
- Garcia JH, Cox JV, Hudgins WR. 1971. Ultrastructure of the microvasculature in experimental cerebral infarction. *Arch Neuropathol (Berl)* 18:273-285.
- Garcia JH, Kalimo H, Kamijyo Y. 1977. Cellular events during partial cerebral ischemia. 1. Electron microscopy of feline cerebral cortex after middle cerebral artery occlusion. *Virchows Arch (B)* 25:191-206.
- Garcia JH, Kamijyo Y. 1974. Cerebral infarction. Evolution of histopathological changes after occlusion of a middle cerebral artery in primates. *J Neuropathol Exp Neurol* 33:409-421.
- Garcia JH, Liu K-F, Ho K-L. 1995a. Neuronal necrosis after middle cerebral artery occlusion in Wistar rats progresses at different time intervals in the caudoputamen and the cortex. *Stroke* 26:636-643.
- Garcia JH, Liu KF, MacKenzie ET, Lassen NA, Baron JC. 1995b. Incomplete and complete brain infarcts in baboons with middle cerebral artery occlusion (Abstract). *Cerebrovasc Dis* 5:235.
- Garcia JH, Liu KF, Yoshida Y, Lian J, Chen S, del Zoppo GJ. 1994. Influx of leukocytes and platelets in an evolving brain infarct (Wistar rat). *Am J Pathol* 144:188-199.
- Garcia JH, Lowry SL, Briggs L, Mitchem HL, Morawetz R, Halsey JH, Conger KA. 1983a. Brain capillaries expand and rupture in areas of ischemia and reperfusion. In: Reivich M, Hurtig HI, eds. *Cerebrovascular Diseases*. New York: Raven Press. p 169-182.
- Garcia JH, Mitchem HL, Briggs L, Morawetz R, Hudetz AG, Hazelrig JB, Halsey JH Jr, Conger KA. 1983b. Transient focal ischemia in subhuman primates: Neuronal injury as a function of local cerebral blood flow. *J Neuropathol Exp Neurol* 42:44-60.
- Garcia JH, Yoshida Y, Chen H, Li Y, Zhang ZG, Liam J, Chen S, Chopp M. 1993. Progression from ischemic injury to infarct following middle cerebral artery occlusion in the rat. *Am J Pathol* 142:623-635.
- Ginsberg MD, Busto R. 1989. Rodent models of cerebral ischemia. *Stroke* 20:1627-1642.
- Grau AJ, Sigmund R, Hacke W. 1994. Modification of platelet aggregation by leukocytes in acute ischemic stroke. *Stroke* 25:2149-2152.
- Hamann GF, Okada Y, Fitridge R, del Zoppo GJ. 1995. Microvascular basal lamina antigens disappear during cerebral ischemia and reperfusion. *Stroke* 26:2120-2126.
- Hanson SR, Harker LA. 1987. Baboon models of acute arterial thrombosis. *Thromb Haemost* 58:801-805.
- Heo JH, Lucero J, Abumiya T, Koziol JA, Copeland BR, del Zoppo GJ. 1999. Matrix metalloproteinases increase very early during experimental focal cerebral ischemia. *J Cereb Blood Flow Metab* 19:624-633.
- Hosomi N, Lucero J, Heo JH, Koziol J, Copeland BR, del Zoppo GJ. 2001. Rapid differential endogenous plasminogen activator expression after acute middle cerebral artery occlusion. *Stroke* 32:1341-1348.
- Huang J, Mocco J, Choudhri TF, Poisk A, Opilskis SJ, Emerson R, DelaPaz RL, Khandji AG, Pinsky DJ, Connolly S. 2000. A modified transorbital baboon model of reperfused stroke. *Stroke* 31:3054-3063.
- Hudgins RW, Garcia JH. 1970. Transorbital approach to the MCA of the squirrel monkey: A technique for experimental cerebral infarction applicable to ultrastructural studies. *Stroke* 1:107-111.
- Jones TH, Morawetz RB, Crowell RM, Marcoux FW, Fitzgibbon SJ,

- DeGirolami U, Ojemann RG. 1981. Thresholds of focal cerebral ischemia in awake monkeys. *J Neurosurg* 54:773-782.
- Kawaguchi M, Kimbro JR, Drummond JC, Cole DJ, Kelly PJ, Patel PM. 2000. Isoflurane delays but does not prevent cerebral infarction in rats subjected to focal ischemia. *Anesthesiology* 92:1335-1342.
- Kleim JA, Barbay S, Nudo RJ. 1998. Functional reorganization of the rat motor cortex following motor skill learning. *J Neurophys* 80:3321-3325.
- Liu XG, Branston NM, Kawaguchi M, Symon L. 1992. A model of acute focal ischemia in the territory of the anterior cerebral artery in baboons. *Stroke* 1:40-44.
- Michenfelder JD, Milde JH. 1975. Influence of anesthetics on metabolic, functional and pathological responses to regional cerebral ischemia. *Stroke* 6:405-410.
- Molinari GF, Moseley JJ, Laurent JP. 1974. Segmental middle cerebral artery occlusion in primates: An experimental method requiring minimal surgery and anesthesia. *Stroke* 5:334-339.
- Mori E, Chambers JD, Copeland BR, Arfors K-E, del Zoppo GJ. 1992. Inhibition of polymorphonuclear leukocyte adherence suppresses no-reflow after focal cerebral ischemia. *Stroke* 23:712-718.
- Mori E, Ember J, Copeland BR, Thomas WS, Koziol JA, del Zoppo GJ. 1995. Effect of tirilazad mesylate on middle cerebral artery occlusion/reperfusion in non-human primates. *Cerebrovasc Dis* 5:342-349.
- Mori E, Tabuchi M, Yoshida T, Yamadori A. 1988. Intracarotid urokinase with thromboembolic occlusion of the middle cerebral artery. *Stroke* 19:802-812.
- Moudgil GC, Gordon J, Forrest JB. 1984. Comparative effects of volatile anesthetic agents and nitrous oxide on human leukocyte chemotaxis in vitro. *Can Anaesth Soc J* 31:631-637.
- Moudgil GC, Pandya AR, Ludlow DJ. 1981. Influence of anesthesia and surgery on neutrophil chemotaxis. *Can Anaesth Soc J* 28:232-238.
- Nudo RJ, Milliken GW. 1996. Reorganization of movement representations in primary motor cortex following focal ischemic infarcts in adult squirrel monkeys. *J Neurophys* 75:2144-2149.
- Okada Y, Copeland BR, Mori E, Tung M-M, Thomas WS, del Zoppo GJ. 1994. P-selectin and intercellular adhesion molecule-1 expression after focal brain ischemia and reperfusion. *Stroke* 25:202-211.
- Paxinos G, Watson C. 1986. *The Rat Brain in Stereotaxic Coordinates*, plates 17-20. San Diego: Academic Press.
- Pulsinelli W, Brierley J, Plum F. 1982. Temporal profile of neuronal damage in a model of transient forebrain ischemia. *Ann Neurol* 11:491-498.
- Pulsinelli WA. 1985. Selective neuronal vulnerability: Morphological and molecular characteristics. *Prog Brain Res* 63:29-37.
- Pulsinelli WA, Duffy TE. 1983. Regional energy balance in rat brain after transient forebrain ischemia. *J Neurochem* 40:1500-1503.
- Rosenblum WI, Wormley B. 1995. Selective depression of endothelium-dependent dilations during cerebral ischemia. *Stroke* 26:1877-1881.
- Schmid-Schönbein GW, del Zoppo GJ. 1993. Anti-PMN leukocyte strategies and their application to focal cerebral ischemia. In: del Zoppo GJ, Mori E, Hacke W, eds. *Thrombolytic Therapy in Acute Ischemic Stroke II*. Heidelberg: Springer-Verlag, p 245-255.
- Shinozaki K, Kawasaki T, Kambayashi J, Sakon M, Shiba E, Ou M, Mori T. 1992. Species differences in platelet aggregation induced by platelet-activating factor (PAF). *Methods Find Exp Clin Pharmacol* 14:663-665.
- Siesjö B. 1992. Pathophysiology and treatment of focal cerebral ischemia. *J Neurosurg* 77:169-184.
- Spetzler RF, Selman WR. 1979. New design for an implantable vessel occluder. *Surg Neurol* 13:317-319.
- Spetzler RF, Selman WR, Weinstein P, Townsend J, Mehdoric M, Telks D, Crumrine RC, Macko R. 1980. Chronic reversible cerebral ischemia: Evaluation of a new baboon model. *J Neurosurg* 7:257-261.
- STAIR [Stroke Therapy Academic Industry Roundtable]. 1999. Recommendations for standards regarding preclinical neuroprotective and restorative drugs. *Stroke* 30:2752-2758.
- Sundt TM, Jr., Waltz AG. 1966. Experimental cerebral infarction: Retro-orbital, extradural approach for occluding the middle cerebral artery. *Mayo Clin Proc* 41:159-168.
- Symon L. 1975. Experimental model of stroke in the baboon. *Adv Neurol* 10:199-212.
- Tagaya M, Haring H-P, Stuver I., Wagner S, Abumiya T, Lucero J, Lee P, Copeland BR, Seiffert D, del Zoppo GJ. 2001. Rapid loss of microvascular integrin expression during focal brain ischemia reflects neuron injury. *J Cereb Blood Flow Metab* 21:835-846.
- Tagaya M, Liu K-F, Copeland B, Seiffert D, Engler R, Garcia JH, del Zoppo GJ. 1997. DNA scission after focal brain ischemia: Temporal differences in two species. *Stroke* 28:1245-1254.
- Thomas WS, Mori E, Copeland BR, Yu J-Q, Morrissey JH, del Zoppo GJ. 1993. Tissue factor contributes to microvascular defects following cerebral ischemia. *Stroke* 24:847-853.
- Vajda J, Branston NM, Ladds A, Symon L. 1985. A model of selective experimental ischaemia in the primate thalamus. *Stroke* 16:493-501.
- von Andrian UH, Chambers JD, McEvoy LM, Bargarze RF, Arfors K-E, Butcher EC. 1991. Two-step model of leukocyte-endothelial cell interaction in inflammation: Distinct roles for LECAM-1 and the leukocyte β_2 integrins in vivo. *Proc Natl Acad Sci U S A* 88:7538-7542.
- von Kummer R, Bozzao L, Manelfe C. 1995. *CT Diagnosis of Hemispheric Brain Infarction*. Heidelberg: Springer-Verlag.
- von Kummer R, Weber J. 1997. Brain and vascular imaging in acute ischemic stroke: The potential of computed tomography. *Neurology* 49(Suppl 4):S52-S55.
- Watanabe O, Bremer AM, West CR. 1977. Experimental regional cerebral ischemia in the middle cerebral artery territory in primates. II: Effects on brain water and electrolytes in the early phase of MCA stroke. *Stroke* 8:71-76.
- Yonas H, Gur D, Claassen D, Wolfson SK, Jr., Moosy J. 1990. Stable xenon-enhanced CT measurement of cerebral blood flow in reversible focal ischemia in baboons. *J Neurosurg* 73:266-273.
- Young AR, Touzani O, Derlon J-M, Sette G, MacKenzie ET, Baron J-C. 1997. Early reperfusion in the anesthetized baboon reduces brain damage following middle cerebral artery occlusion: A quantitative analysis of infarction volume. *Stroke* 28:632-638.
- Zivin JA, Grotta JC. 1990. Animal stroke models: They are relevant to human disease. *Stroke* 21:981-983.