

Assessment of Cognitive and Motor Deficits in a Marmoset Model of Stroke

Jonathan W. B. Marshall and Rosalind M. Ridley

Abstract

The Stroke Therapy Academic Industry Roundtable noted the need for standardized, well-accepted primate models of stroke to help develop both neuroprotective and restorative therapies. One primate model has been developed using the marmoset, a small New World species of monkey, in which long-term functional deficits can be assessed. The surgery and postoperative care of the animals is described, as well as the behavioral tests used to quantify the postoperative disability. The types of deficits seen are illustrated by reference to some of the findings with neuroprotective treatments. Nevertheless, the long-term nature and consistency of the motor deficits make this model ideal for assessing the worth of restorative therapies.

Key Words: marmoset; motor deficit; neglect; nonhuman primate; stroke

Introduction

Numerous neuroprotective drugs appeared to be promising candidates for the treatment of stroke in preclinical studies but have later failed to show efficacy when tested in the clinic. One explanation for this incongruity is that the designs of the clinical trials were ill conceived in that dose selection, length of the therapeutic time window, and patient selection may have been poorly chosen (Green 2002).

Another explanation for the failure of these drugs in the clinic concerns the relevance of animal models to the human condition of stroke (Molinari 1988; Wiebers et al. 1990). However, whatever the cause of the stroke, be it pathological or surgical, there is little doubt that ischemic cell death is biochemically similar in animals and humans. Nevertheless, to address some of the concerns about preclinical drug studies, a roundtable was formed consisting of experts from both academia and industry (STAIR 1999). This forum proposed a set of guidelines for preclinical neuroprotective and

restorative drug development. The recommendations included greater use of functional tests in animal models of stroke; long-term outcome measures; and the need for well-characterized primate models, which would preferably include some aspect of behavioral measurement.

The requirement for behavioral testing stems from the fact that improvement in functional outcome is what matters to the stroke sufferer and it is also used as the major endpoint in clinical trials (NINDH 1995). Furthermore, the size of the lesion does not necessarily correlate with behavior in animals nor in humans. Long-term outcome measures are needed to ensure that drugs are permanently salvaging the tissue rather than just delaying or slowing the pathological progression of the lesion. Primate models of stroke are necessary because it is often difficult to extrapolate findings directly from rodents to humans without some intermediary species. Monkeys, considering their closeness in the phylogenetic tree to humans compared with rats, can provide that much needed stopgap. Although stroke research has used baboons, and to a lesser extent macaques, for more than 35 yr (Crowell et al. 1970; del Zoppo et al. 1986; Garcia and Kamijyo 1974; Symon 1975; Young et al. 1997), there are many practical problems of using these species of monkeys, for example, handling these large animals when considerable postoperative care is needed. There is also increasing difficulty and expense in obtaining, keeping, and breeding Old World monkeys (Baker and Ridley 1986) as well as ethical concerns.

Along these trains of thought, we developed a primate model of stroke using a New World species of monkey, the common marmoset (*Callithrix jacchus*), in which long-term functional outcome is assessed (Marshall and Ridley 1996). This article describes our primate model including the surgery, postoperative care, and behavioral tests we have used to quantify the level of disability that follows an induced stroke. To illustrate these tests, the article describes some of results achieved with the neuroprotective agents clomethiazole (Marshall et al. 2000a), AR-R15896AR (Marshall et al. 2000b), and NXY-059 (Marshall et al. 2001). Although many strokes spontaneously reperfuse in man, a substantial number do not do so within a short time, if at all. Our model therefore uses a permanent occlusion of an artery to mimic these types of stroke. Furthermore, it is thought that permanent models may provide a more stringent test of neuroprotective efficacy of drugs than do reperfusion models and are therefore useful for filtering out compounds before costly clinical development.

Jonathan W. B. Marshall, B.Sc. (Hons), Ph.D., and Rosalind M. Ridley, M.A., Ph.D., Sc.D., are members of the MRC Comparative Cognition Team, Department of Experimental Psychology, University of Cambridge, Downing Street, Cambridge, UK.

Marmoset

The marmoset is a New World species of monkey, is one of the smallest true primates, and breeds readily in captivity, obviating the need to use wild-caught animals. Laboratory-bred marmosets weigh between 300 and 500 g when mature (i.e., ≥ 18 mo old). The marmoset is a nongyrencephalic species, and although it is only a little larger in body weight than a rat, its brain size is approximately 8 times the size and its white to gray matter ratio is larger than in rodents. This latter point may be important in neuroprotective stroke research (Muir and Grosset 1999). Marmosets are easy to handle, which is a benefit for administering postoperative care, and they are readily trained on behavioral tasks without the need for restrictive diets because they have a strong penchant for sweet foods (especially marshmallow). Experimental animals are housed in pairs, usually male-female pairs, with the male vasectomized. There is now extensive literature on the use of this species in biological research; some useful articles include Baker and Ridley (1986) and Hearn (1987).

Surgery

When we first started to develop this model, we looked at the various methods of arterial occlusion used in established animal models of stroke. Unfortunately, none were suitable for our needs. For example, the middle cerebral artery of the marmoset lies deep within the lateral sulcus and therefore the traditional approach used in the rat of a small burr hole in the lateral side of the skull to visualize this vessel (Tamura et al. 1981) was not possible. Furthermore, the intraluminal thread model (Longa et al. 1989) was also not viable inasmuch as marmosets have large kinks in their internal carotid arteries, which would prevent the passing of the cannulae. The retro-orbital approach used in large primates and cats was also not apt because it was necessary for the monkeys to perform behavioral tests postoperatively, which necessitates that their primary visual system remain intact. Therefore, to gain access to the brain and the middle cerebral artery, we have used a surgical technique routinely carried out in our laboratory for many years in cognitive studies and have turned a large bone flap.

To accomplish the procedure described above, the marmosets are anesthetized with Saffan (alphaxolone [9 mg/mL]/alphadolone acetate [3 mg/mL], 0.15 mL/100 g; Glaxo Vet Ltd, Uxbridge, UK) administered intramuscularly. The drug produces a reasonably long anesthetic duration of 1 to 1.5 hr. Anesthetic depth is assessed by various means including pedal withdrawal reflex and top-up anesthetic administered as required. Ketamine, which is routinely used as a premedication for other surgical procedures in this species, is not used in these stroke studies due to its interaction at the *N*-methyl D-aspartate receptor. It must be noted that alphaxalone, a component of the Saffan anesthetic, potentiates GABA, the mechanism by which clomethiazole is

thought to be neuroprotective in animal models of stroke (Green 1998). However, whereas clomethiazole was neuroprotective against global cerebral ischemia in the gerbil, alphaxalone was not (Cross et al. 1991), suggesting it has little if any neuroprotective action. Besides, in our studies with our experimental neuroprotective agents, both control and drug-treated groups of monkeys receive equivalent amounts of this anesthetic.

Once the monkey is fully anesthetized, the head and base of the tail are shaved (the tail for measurement of physiological variables) and cleansed before surgery with Hibiscrub and Betadine. The monkey is then placed on a heated blanket and covered to maintain normal body temperature, and the head is secured in a stereotaxic frame. A standard rat stereotaxic frame (e.g., David Kopf Instruments no. 900) fitted with a primate head holder is used. A curved incision is then made through the skin across the top of the head between the ears and the skin retracted anteriorly and posteriorly to expose the cranium. The top of the right-hand temporalis muscle is scraped back. Two small drill holes are then made either side of the sagittal sinus 2 mm above the eye orbits and a farther two holes at the back of the skull, again on either side of the sagittal sinus. Using a small dental circular saw, the skull is cut through approximately 270° joining the holes, and care is taken not to damage the underlying meninges or brain. On easing up this bone flap, the remaining bone, under the left-hand temporalis muscle, cracks with the muscle acting as a hinge, exposing the underlying brain.

A stellate incision is then made in the meninges in the area of the right frontal lobe, with one arm extending to the frontal pole, one to the sagittal sinus and the last to a posterior ventral position overlying the temporal lobe. The distal portions of the middle cerebral artery (MCA¹) can be seen leaving the top of the lateral sulcus, supplying the frontal, parietal and temporal cortices. To gain access to the more proximal portion, the frontal lobe is carefully lifted allowing the surgeon access to the orbital surface of the frontal lobe. With the aid of an operating microscope and by following the path of the olfactory tract, the MCA can be seen at the junction of the frontal and temporal lobes as it crosses the olfactory tract but before the artery enters the lateral sulcus. Using small bipolar forceps attached to a Surgitron FFPF electrocoagulation unit, the right M1 segment of the MCA is then permanently occluded and bisected 2 mm medial to the olfactory tract.

Occlusion of the M1 segment disrupts blood flow to the whole MCA territory including the subcortical structures, the caudate, and the putamen because the occlusion is before the lenticulostriate arteries, which branch off to serve these areas. Our earlier work (Marshall and Ridley 1996) had occluded the MCA more distally, at a point on the M2 segment. This primarily led to a cortical infarct of the MCA

¹Abbreviations used in the article: MCA, middle cerebral artery; pMCAO, permanent middle cerebral artery occlusion.

territory with only a small amount of damage to the lateral putamen. We ultimately found that occlusion at this more distal site produced more varied functional deficits and therefore shifted our site of occlusion to the M1 segment which has produced a more consistent behavioral outcome.

After arterial occlusion, the meninges are sutured using coated Vicryl (7/0 gauge). The cranium is replaced and the opposing temporalis muscles are sewn to each other to hold the flap in place. Finally, the skin is sewn using coated Vicryl (3/0 gauge).

After surgery, monkeys are placed in incubators to maintain body temperature during recovery from anesthesia. They remain there for 3 to 5 days and are nursed until they are capable of self-care (see Postoperative Care).

Physiological Variables

During surgery, blood pressure, heart rate, blood oxygen saturation (pO_2) levels and temperature can be measured by noninvasive methods. Blood pressure is monitored using an Ultrasonic Doppler Flow Detector (model 811-B; Perimed UK Ltd., Bury St Edmunds, UK), with the probe attached to the underside of the tail below an inflatable cuff and pressure gauge. Heart rate and pO_2 levels are monitored with a Tiger pulse oximeter (Thames Medical, West Sussex, UK), with the probe attached to a foot pad, and body temperature is measured with a rectal thermometer. Recordings are taken at 10-min intervals during surgery. After surgery, when the animals are no longer anesthetized and are mobile, it is difficult to measure blood pressure, heart rate, and pO_2 levels. However, rectal temperature can be measured with light restraint of the animals.

Drug Treatment

In the studies we have conducted to date, our interest has been to determine the efficacy of the drugs in a primate model of stroke rather than the therapeutic time window of each compound. Therefore, the timing of drug administration, although it has been after the arterial occlusion, was chosen to maximize the potential beneficial effects of drug treatment (i.e., all of the drugs have been administered shortly after arterial occlusion). We have not as yet examined the potential therapeutic time window in this species, an important consideration before taking drugs through to clinical trials. Future studies will examine this issue.

The drug dosing regimens used to date were designed to match the intended plasma levels in clinical trials. Drug dosing is one of several reasons that can account for the failure of clinical trials (Green 2002) because the high plasma levels that were necessary to produce neuroprotection in animal models could not be replicated in the clinic due to significant adverse side effects (Muir and Lees 1995).

Typically we have administered the experimental drug 5 min after permanent middle cerebral artery occlusion

(pMCAO¹), as a 1-mL intravenous infusion of either saline or drug, using a 22-g intravenous catheter, along with the subcutaneous implantation of primed osmotic minipumps (Alzet model 2001D) to provide prolonged drug or saline infusion. These pumps are inserted into a 4-cm-long pouch made between the shoulder blades at the start of surgery. Due to the infusion properties of the model 2001D Alzet minipumps, the minipumps need to be replaced 24 hr after pMCAO with additional minipumps under Saffan anesthesia to provide continuous drug administration for a total of 48 hr. The pumps are then removed. It is possible to use a single large minipump (e.g., model 2ML1, which infuses drugs at a rate 10 μ L/hr for 1 wk). However, we believe that these larger pumps would be uncomfortable and restrict the monkey's movement, so two to three smaller pumps are preferable. A 0.5-mL blood sample can be taken 24 hr after pMCAO for analysis of blood plasma level.

Postoperative Care

Marmosets tolerate this surgical procedure remarkably well. After surgery, monkeys are placed in incubators to maintain body temperature during recovery from anesthesia. On the day of surgery, while still anesthetized, the monkeys may be given 5 mL of sterile saline intraperitoneally to ensure adequate hydration. We routinely administer a subcutaneous injection of 1 mg/kg of flunixin meglumine (Finadyne, Schering-Plough, Mildenhall, UK), a long-acting analgesic, once a day for the first 2 days after surgery.

For the first 48 hr, monkeys have difficulty caring for themselves as they accommodate to their unilateral impairments. Typical impairments include left arm hemiparesis, abnormal grasp reflex, left-sided neglect, and rotation. For the most part, the best form of medication for the first 48 hr is peace and quiet. However, during these first few days, the animals need hand feeding and the administration of regular oral fluids. Lectade (Pfizer, Sandwich, Kent, UK), an oral rehydration therapy, sweetened and flavored with banana milk shake mix such as Nesquik (Néslé, UK), is usually readily taken. The monkeys require approximately 20 mL of fluids per day. The monkeys are also fed via syringe a baby "porridge" mix such as Farley's Breakfast Fruit and Yoghurt meal (Heinz Co. Ltd., Middlesex, UK). When they are ready for more solid food, the monkeys can be hand fed thin slices of banana. The monkeys remain in their incubators until they are capable of self-care, which usually takes 3 to 5 days. We have been undertaking this research for several years now and have conducted more than 100 of these surgeries. Only one monkey has been euthanized due to poor recovery from this procedure. The overall mortality rate from this procedure is less than 10%, and most deaths occurred during the early development of the model.

When first returned to their home cages, the monkeys may have difficulty climbing and jumping around the cage. The cage is therefore lined with some soft lining material (e.g., VetBed [Petlife International Limited, Bury St. Ed-

munds, UK]). However, the monkeys rapidly accommodate to their contralesional incapacity and soon freely jump and climb around their cages. Although the monkeys do exhibit some postural abnormalities with occasional slips with their contralesional hands and feet on the cage perches and poles, a casual observer would find it difficult to distinguish between these operated monkeys and normal monkeys 2 wk after surgery. However, behavioral tests quickly reveal the level of disability.

Behavioral Tasks

All behavioral testing is performed in a modified home cage with an internal Plexiglas enclosure to prevent the monkeys hanging upside down from the bars while they perform the tasks. The enclosure, entered from the rear, contains a small central perch on which the monkeys stand while performing the tasks. Before surgery, all monkeys are extensively trained and tested on the tasks. Initially, they are habituated to the test apparatus in their home cage, along with regular hand feeding of small marshmallow pieces at the front of the cage by the experimenter. After a few days, the monkeys become accustomed to the test apparatus and the experimenter and can be introduced into the modified test cage. The monkeys are then presented with the test apparatus as it would be presented in test trials, with a plentiful supply of reward but with no time limits imposed. Over a couple of weeks of regular practice, the monkeys become highly proficient at all of the tasks and then can be formally pre-operatively tested. This training period typically takes 3 to 4 wk. The monkeys are then retested 3 and 10 wk after surgery.

Hill and Valley Staircase Tasks

In the Hill and Valley Staircase tasks, the monkeys are required to reach through vertical slots in a Plexiglas screen attached to the front of the cage in an effort to retrieve food rewards from the steps of two staircases outside the cage (Figure 1). A small piece of marshmallow (2- to 3-mm diameter) is placed on each step of the staircases to give a total of five pieces on each side. The monkeys are allowed 3 min to retrieve all of the food bits and are scored by an observer sitting 1 to 2 m away from the cage front. Only successful reaches, defined as food taken securely through the slot, are counted. The score for each piece depends on the distance from the relevant slot (score 1 for the nearest piece, 5 for the farthest piece). The total score is summed to give a maximum score of 15 for each side.

In the Hill task, there are two laterally positioned slots and the staircases rise toward the center of the apparatus. The monkeys therefore use their right hand to reach to the right staircase and their left hand to the left staircase. In the Valley task, there is one centrally positioned slot, and the staircases rise toward the outside of the apparatus. The right

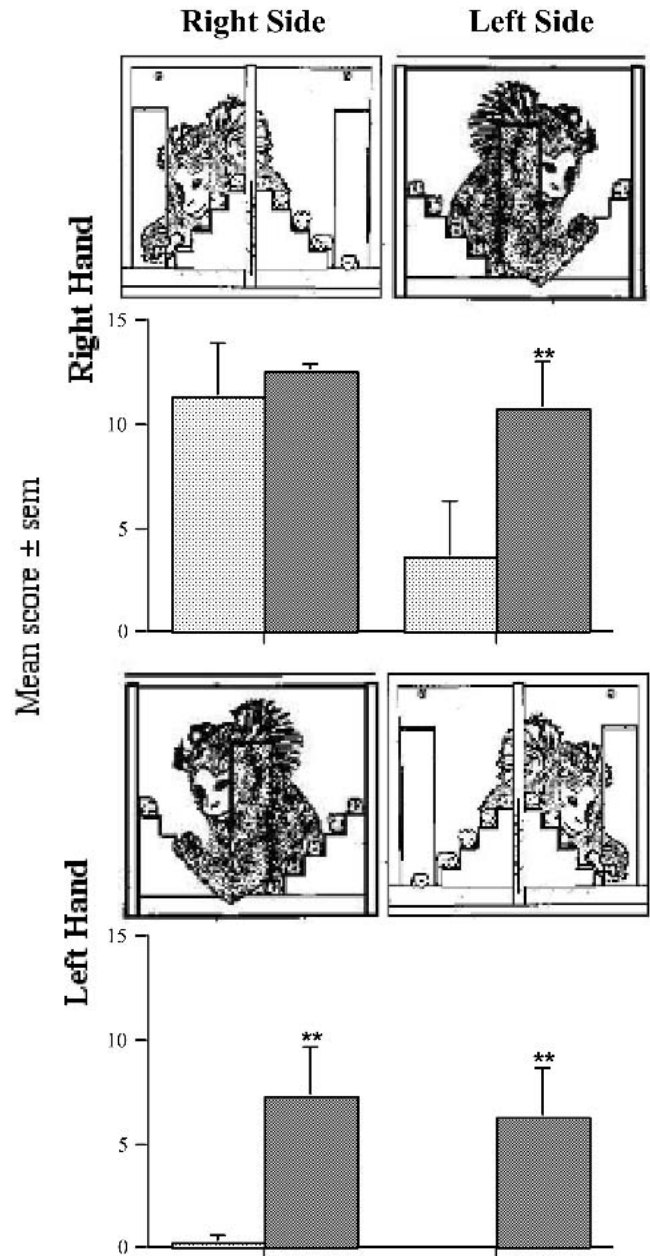


Figure 1 Hill and Valley Staircase tasks. Results are shown as mean score (\pm standard error of the mean [sem]) in successfully retrieving food rewards with the monkeys' left and right arms, when assessed 3 wk postoperatively. The saline-treated group is shown as hatched columns and the NXY-059-treated group as gray columns. **, $p < 0.01$ significant difference between the two groups.

arm is therefore used to reach to the left staircase and vice versa.

Each monkey is tested with both designs of staircase in a random order, such that they receive three trials with each design. Examining the use of each arm into either hemisphere allows the effects of a unilateral motor impairment, confined to one arm in either hemisphere, to be dis-

sociated from a unilateral perceptual spatial impairment, confined to one hemisphere with either arm.

In Figure 1, the results obtained when marmosets were tested 3 wk after pMCAO on the Hill and Valley staircase tasks are shown. In the study shown (Marshall et al. 2001), one group of marmosets was treated with NXY-059, a free radical trapping agent, and the other with saline. As can be seen in the graphs, saline-treated monkeys reveal two discrete deficits. The first deficit is an inability to retrieve marshmallow pieces successfully from either hemisphere with their contralesional, left arm. The second deficit is related to retrieving rewards in contralesional space with their nonaffected ipsilesional, right arm due to perceptual problems in one side of space. This latter deficit is known as spatial neglect and in patients is mainly associated with stroke-induced damage to the right hemisphere. In humans, spatial neglect is incapacitating and can markedly hinder the patient's rehabilitation from a stroke (Robertson et al. 1993). Typical problems of individuals with spatial neglect may include bumping into objects on their contralesional side, failure to shave or dress this side of the body, and omitting details from the contralesional side when copying drawings. The widely held view is that it is due to a disruption in higher order cognitive processing rather than a disturbance of the primary visual system.

NXY-059 significantly reduced both the motor impairment with the contralesional, left arm and the degree of spatial neglect in this study. Although the spatial deficit recovers with time (there is usually little evidence of neglect 10 wk after surgery), as it does in humans, the motor deficit persists with no recovery over 20 wk of testing (Marshall et al., manuscript in preparation).

Six-Tube Search Task

The Staircase tasks are very useful for separating motor from spatial deficits. However, one explanation for the spatial deficit in the staircase task is that the monkeys are unable to disengage their attention from the visible rewards on the ipsilesional, right side of the staircase task thereby reducing the number of reaches to the contralesional, left side — rather than that the monkeys exhibit a true neglect of one side of space. We have therefore developed other more specific tasks for understanding the spatial deficit, the first of which is the Six-Tube Search task. In this task, the monkeys are required to find a marshmallow piece hidden in any one of six locations (Figure 2). Because there is only one reward available on each trial, this task is a test of spatial neglect rather than a disengagement deficit or extinction.

Six black plastic tubes (diameter: 3 cm; depth: 5 cm) separated by 0.2 cm are fixed to a Plexiglas strip, which is presented horizontally at the front of the home cage. Monkeys can reach into the tubes only if they enter the enclosure in the cage and stand on the small central perch. Only one tube is baited with a marshmallow reward, and the time taken for the monkey to find it, starting from when the tubes

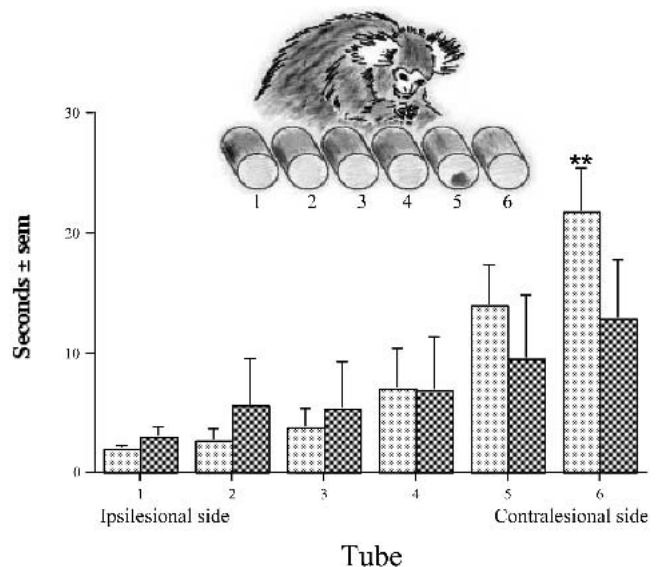


Figure 2 Six Tube Search task. Results are shown as mean time (\pm standard error of the mean [sem]) to find the food rewards hidden in each one of the six tubes from the monkeys' far right (tube 1) to their far left (tube 6), when assessed 3 wk postoperatively. The saline-treated group is shown as hatched columns and the AR-R15896AR-treated group as gray columns. **, $p < 0.01$ significant difference between the two groups.

are first presented, or from when the monkey first jumped on the central perch, is recorded. Once the reward has been retrieved, or 30 sec have passed, the array of tubes is removed and another tube is baited. This sequence is carried out 30 times with the tubes baited in a pseudorandom order such that each of the six tubes is baited five times.

In Figure 2, results are shown of instances in which monkeys treated with either an *N*-methyl D-aspartate antagonist, AR-R15896AR, or saline were tested 3 wk after pMCAO on this task. Saline-treated monkeys easily found the reward if it was hidden in the three most ipsilesional tubes. However, when the reward was hidden in the contralesional tubes, the monkeys had increasing problems at finding these rewards the farther lateral the rewarded tube was in contralesional space, a clear sign of spatial neglect. AR-R15896AR treatment ameliorated this deficit. Unlike the motor deficit, spatial neglect does improve spontaneously although there may be some residual symptoms in monkeys 10 wk after pMCAO (Marshall et al. 2000b).

Two-Tube Choice Test

The Two-Tube Choice task is a test of "extinction" or disengagement deficit, that is, the tendency for attention to items in ipsilesional hemisphere to "overshadow" attention to items in contralesional hemisphere (Barbieri and De Renzi 1989). In this test, two black plastic tubes (diameter: 3 cm; depth: 5 cm) fixed to small Plexiglas strips 2 cm apart from

one another, with a food reward in each tube, are presented to the monkey (Figure 3). Once the monkey has reached into one tube and retrieved a reward, the choice of side is noted and the tubes are removed and rebaited. The tubes are randomly presented in front, and to the left or right sides, of the monkey, in a random order such that there are 10 trials at each position and a total of 30 trials. Following right-hand-sided pMCAO, monkeys reached almost exclusively to the right of the two rewarded tubes, even when both tubes were presented on the monkey's ipsilesional side, such that this tube is less accessible than the left tube, ignoring the left tube and preferred tube preoperatively (Marshall et al. 1999). This deficit is shown in Figure 3, reflecting data taken from a study that examined clomethiazole, which reduced this deficit.

Rotation

Although rotation is rarely seen in the clinic, a bias to rotate in one direction can be a sensitive marker of unilateral brain dysfunction in animal models of disease. The number and direction of spontaneous 360° rotations of the monkeys while they are housed singly in the home cage, with nest box and angled perches removed, are recorded for a 15-min period by an experimenter who sits approximately 2 to 3 m

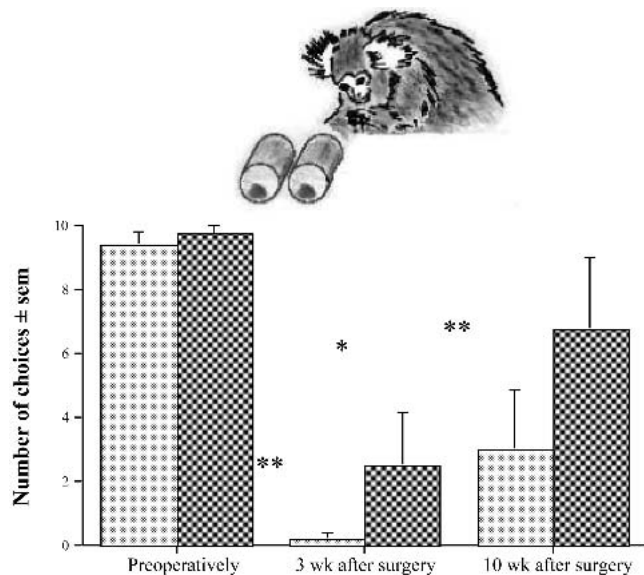


Figure 3 Two Tube Choice test. Results are shown as the mean number of choices (\pm standard error of the mean [sem]) to the left, contralesional tube when the pair were presented on the monkey's right side, when assessed preoperatively, and at 3 and 10 wk post-operatively. The saline-treated group data are shown as hatched columns and the clomethiazole-treated group as gray columns. *, $p < 0.05$ significant difference compared with preoperative score; **, $p < 0.01$ significant difference compared with preoperative score.

away from the cage in the home room. Marmosets predominantly rotate ipsilesionally when tested both 3 and 10 wk after surgery, and neuroprotective drugs can reduce this deficit. For example, 3 wk after surgery, saline-treated monkeys made $95 \pm 5\%$ of rotations to the ipsilesional side, whereas NXY-059-treated animals rotated only $68 \pm 12\%$ to this side.

Histology

To ascertain whether these neuroprotective compounds do in fact reduce the size of the infarct requires volumetric analysis of the lesion. After completion of behavioral testing, the monkeys are deeply anesthetized and perfused transcardially with 200 to 300 mL of saline followed by 250 to 300 mL of 10% formal saline. The brains are removed and immersed in 10% formal saline. Before blocking and paraffin wax embedding, the brains are examined to ensure that the MCA had been bisected at the site adjacent to the olfactory tract. Coronal sections (8 μ m) are taken at regular levels through the brains within the areas of visible infarct. Sections are stained with solochrome cyanine and cresyl violet counter staining.

Images of stained sections, at approximately 1-mm intervals through the brain from AP 14.5 to AP 2.5 of the stereotaxic atlas (Stephan et al. 1980), are videocaptured with a digital camera connected to a Leica M420 Wild microscope. Using a computerized image analysis system (Global Lab Image, Data Translation Ltd., UK), the areas of the contralesional hemisphere and of intact ipsilesional hemisphere (i.e., excluding areas of infarct damage) are measured. To adjust for size differences between monkeys, the average area of the contralateral hemisphere of all the monkeys at each stereotaxic level is used to transform all of the measurements to a standard size of brain. The area of tissue damage for each monkey is then calculated by subtracting the area of the ipsilateral hemisphere from the area of the contralateral hemisphere. The results from the NXY-059 study are shown in Figure 4.

By the time the monkeys are perfused, 11 to 12 wk after surgery, the infarcts are large, with tissue loss to the lateral frontal, motor, parietal, and temporal cortex. The damage extends subcortically to the underlying white matter, in most cases with complete loss of both the caudate and putamen. A photomicrograph of a typical lesion is shown in Figure 5. We have compared the damage to specific regions with the specific functional deficits measured. However, no clear relationships have yet emerged.

Conclusion

Stroke is a leading cause of death and a major cause of disability in the Western world. Yet, with the exception of thrombolytic therapy (NINDS 1995), there is no drug treat-

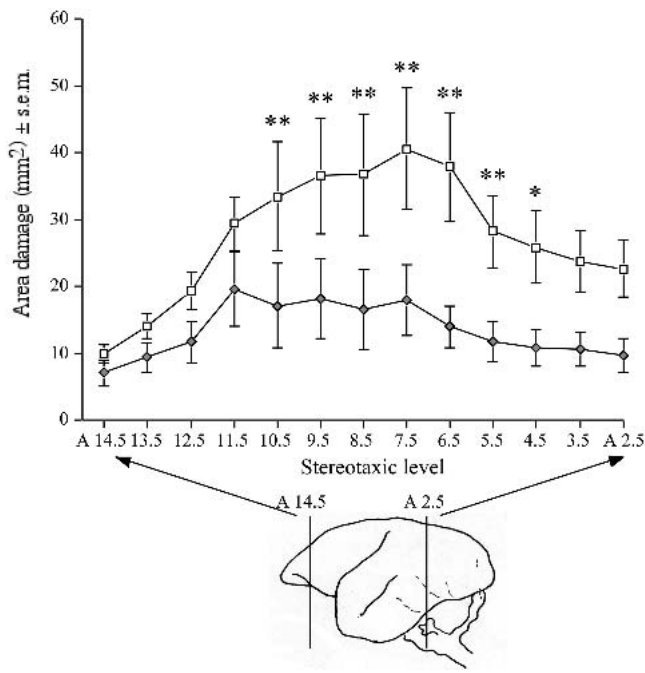


Figure 4 Area of tissue damage across stereotaxic levels. Results show the area ($\text{mm}^2 \pm \text{standard error of the mean}$) of tissue damage to the ipsilateral hemisphere at each stereotaxic level from A 14.5 to A 2.5 of the saline-treated group (white-filled squares), and of the NXY-059-treated group (gray diamonds). *, $p < 0.05$ significant difference between the two groups; **, $p < 0.01$ significant difference between the two groups.

ment. Well-characterized animal models are needed for the development of new therapies that are either neuroprotective or restorative. The model described above has been used predominantly for evaluating the efficacy of neuroprotective treatments in a primate species to ensure positive

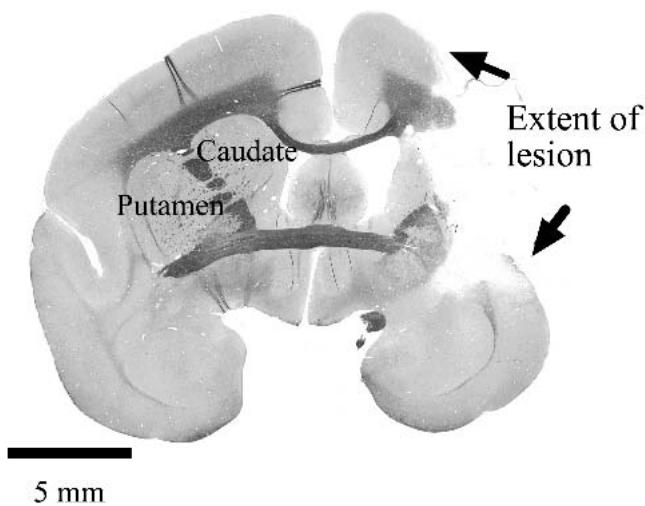


Figure 5 Photomicrograph showing extent of a typical lesion 12 wk after permanent middle cerebral artery occlusion surgery.

effects in a species other than a rodent before proceeding to large-scale Phase III clinical trials. However, as the functional disability produced is highly consistent and long term, this model should also be suitable for testing restorative treatment modalities such as stem cell transplantation.

References

- Baker HF, Ridley RM. 1986. Use of the common marmoset (*Calithrix jacchus*) in psychopharmacological research. In: Joseph MH, Waddington JL, eds. Working Methods in Neuropsychopharmacology. Manchester: Manchester University Press.
- Barbieri C, De Renzi E. 1989. Patterns of neglect dissociation. *Behav Neurol* 2:13-24.
- Cross AJ, Jones JA, Baldwin HA, Green AR. 1991. Neuroprotective activity of chlormethiazole following transient forebrain ischaemia in the gerbil. *Br J Pharmacol* 104:406-411.
- Crowell RM, Olson Y, Klatzo I, Ommaya A. 1970. Temporary occlusion of the middle cerebral artery in the monkey: Clinical and pathological observations. *Stroke* 1:439-448.
- del Zoppo GJ, Copeland BR, Harker LA, Waltz TA, Zyroff J, Hanson SR, Battenberg E. 1986. Experimental acute thrombotic stroke in baboons. *Stroke* 17:1254-1265.
- Garcia JH, Kamijyo Y. 1974. Cerebral infarction: Evolution of histopathological changes after occlusion of a middle cerebral artery in primates. *J Neuropath Exp Neurol* 33:408-421.
- Green AR. 1998. Clomethiazole (Zendra) in acute ischemic stroke: Basic pharmacology and biochemistry and clinical efficacy. *Pharmacol Therapeut* 80:123-147.
- Green AR. 2002. Why do neuroprotective drugs that are so promising in animals fail in the clinic? An industry perspective. *Clin Exp Physiol Pharmacol* 29:1030-1034.
- Hearn JP. 1987. Marmosets and tamarins. In: Poole T, ed. The UFAW Handbook on the Care and Management of Laboratory Animals. Harlow UK: Longman Scientific and Technical. p 568-581.
- Longa EZ, Weinstein PR, Carlson S, Cummins R. 1989. Reversible middle cerebral artery occlusion without craniectomy in rats. *Stroke* 20:84-91.
- Marshall JWB, Cross AJ, Jackson DM, Green AR, Baker HF, Ridley RM. 2000a. Clomethiazole protects against hemineglect in a primate model of stroke. *Brain Res Bull* 52:21-29.
- Marshall JWB, Cross AJ, Ridley RM. 1999. Functional benefit from clomethiazole treatment after focal cerebral ischaemia in a non-human primate species. *Exp Neurol* 156:121-129.
- Marshall JWB, Duffin KJ, Green AR, Ridley RM. 2001. NXY-059, a free radical trapping agent, substantially attenuates the functional disability induced by stroke in a primate species. *Stroke* 32:190-198.
- Marshall JWB, Jones EJ, Duffin KJ, Curry SH, Ridley RM. 2000b. AR-R15896AR, a low affinity, use-dependent, NMDA receptor antagonist, is protective in a primate model of stroke. *J Stroke Cereb Dis* 9:303-312.
- Marshall JWB, Ridley RM. 1996. Assessment of functional impairment following permanent middle cerebral artery occlusion in a non-human primate species. *Neurodegeneration* 5:275-286.
- Molinari GF. 1988. Clinical relevance of experimental stroke models. In: Price TR, Nelson E, eds. Cerebrovascular Diseases. New York: Raven Press. p 19-23.
- Muir KW, Grosset DG. 1999. Neuroprotection for acute stroke: Making clinical trials work. *Stroke* 30:180-182.
- Muir KW, Lees KR. 1995. Clinical experiences with excitatory amino acid antagonists. *Stroke* 26:503-513.
- NINDS [National Institute of Neurological Disorders and Stroke t-PA Stroke Study Group]. 1995. Tissue plasminogen activator for acute ischemic stroke. *N Engl J Med* 333:1581-1587.
- Robertson IH, Halligan PW, Marshall JC. 1993. Prospects for the rehabilitation of unilateral neglect. In: Robertson IH, Marshall JC, eds. Uni-

- lateral Neglect: Clinical and Experimental Studies. Hove UK: Lawrence Erlbaum Associates Ltd. p 279-292.
- STAIR [Stroke Therapy Academic Industry Roundtable]. 1999. Recommendations for standards regarding preclinical neuroprotective and restorative drug development. *Stroke* 30:2752-2758.
- Stephan H, Baron G, Schwerdtfeger WK. 1980. The brain of the common marmoset (*Callithrix jacchus*): A stereotaxic atlas. Berlin: Springer.
- Symon L. 1975. Experimental model of stroke in the baboon. *Adv Neurol* 10:199-212.
- Tamura A, Graham D, McCulloch J, Teasdale G. 1981. Focal cerebral ischemia in the rat. I: Description of technique and early neuropathological consequences following middle cerebral artery occlusion. *J Cereb Blood Flow Metab* 1:53-60.
- Wiebers DO, Adams HP, Jr, Whisnant JP. 1990. Animal models of stroke: Are they relevant to human disease? *Stroke* 21:1-3.
- Young A, Touzani O, Derlon J-M, Sette G, MacKenzie E, Baron J-C. 1997. Early reperfusion in the anaesthetised baboon reduces brain damage following middle cerebral artery occlusion. *Stroke* 28:1471-1476.